

## Slow ventricular response atrial fibrillation related to mad honey poisoning

Osken A., Yaylacı S.<sup>1</sup>, Aydın E., Kocayigit İ., Cakar M.A., Tamer A.<sup>1</sup>, Gündüz H.

Departments of Cardiology, and <sup>1</sup>Internal Medicine, Sakarya University Faculty of Medicine, Sakarya, Turkey

**Address for correspondence:** Dr. Selcuk Yaylacı, Department of Internal Medicine, Sakarya University Faculty of Medicine, 54100 Sakarya, Turkey. E-mail: yaylaci@hotmail.com

### ABSTRACT

Mad honey poisoning which is induced by Grayanotoxin (Andromedotoxin), is also known to have adverse effects in the cardiovascular system leading to different clinical entities. This toxin is produced by a member of the Rhododendron genus of plants of two R. Luteum and R. Panticum. In this article, we presented a case of slow ventricular response atrial fibrillation complaints with nausea, vomiting, dizziness and chest pain about an hour after eating honey produced in the Black Sea Region.

**Key words:** Atrial fibrillation, mad honey, poisoning

### INTRODUCTION

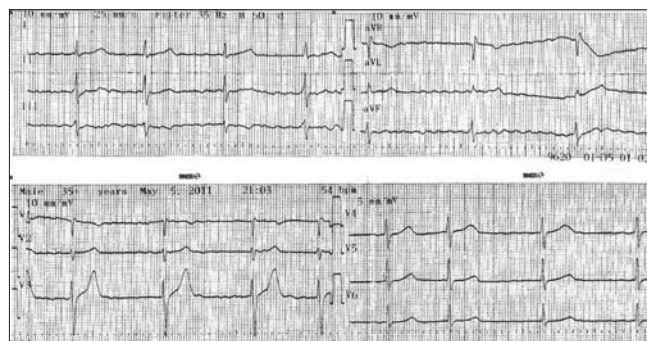
Known as mad honey among the Turkish people and produced in Turkey in the Black Sea region from R. Luteum and R. Panticum's nectar is known to cause severe cardiovascular side effects as well as gastrointestinal symptoms.<sup>[1,2]</sup> Grayanotoksin (andromedotoksin), which is produced by the genus Rhododendron plants is responsible for toxicity.<sup>[1-3]</sup> After ingestion of honey, symptoms suddenly starts and termination of symptoms seldom pass 24 hours.<sup>[1-3]</sup> In this article, we presented a case of slow ventricular response atrial fibrillation complaints with nausea, vomiting, dizziness and chest pain about an hour after eating honey produced in the Black Sea Region.

### CASE REPORT

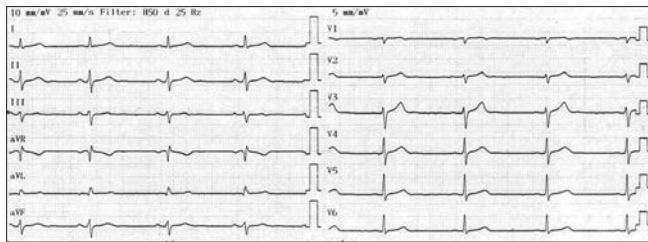
54 year-old male patient presented to our emergency

room with complaints of nausea, vomiting, dizziness and chest pain beginning approximately two hours after honey ingestion. Initial examination showed that the patient was conscious, cooperative, with a heart rate of 40 beats/min and blood pressure of 70/40 mmHg, the other system examinations were normal. Electrocardiogram showed atrial fibrillation with slow ventricular response [Figure 1]. The patient's complaints started approximately one hour after eating two tablespoons of honey produced in the Black Sea region. His medical history did not have a known health problem, not on any medications. The onset of patient's symptoms and history of mad honey consumption

Access this article online	
Quick Response Code:	Website: www.jcdronline.com
	DOI: 10.4103/0975-3583.98904



**Figure 1:** Standard 12-lead electrocardiogram showing atrial fibrillation with a slow ventricular response



**Figure 2:** Normal sinus rhythm

is probably associated with mad honey poisoning. Parenteral hydration with normal saline was provided. 1 mg of intravenous (IV) atropine was administered. After initial treatment, blood pressure and pulse rate remained within the normal range. The control ECG returned to normal sinus rhythm [Figure 2]. Routine laboratory tests, including serum potassium and magnesium level were normal, and cardiac enzymes were not elevated. Echocardiographic examination revealed normal systolic function with no significant valvular disease. Because of intermittent recurrent chest pain, coronary angiography was performed and showed normal coronary arteries. The patient was discharged after 48 hours uneventfully.

## DISCUSSION

Mad honey poisoning is more frequently seen in worldwide countries like Turkey, Nepal, Brazil and Japan.<sup>[1-4]</sup> The honey which was produced from *Rhododendron* genus of plants, is known to have high concentrations of Grayanotoxin and this toxins are responsible for the symptoms of poisoning.<sup>[1]</sup> This honey is also used as an alternative treatment method for gastrointestinal disorders, hypertension, coronary heart disease and also is believed that sexual activity can improve with this honey.<sup>[2]</sup> Typical symptoms of mad honey poisoning are usually gastrointestinal system symptoms, sometimes life-threatening bradycardia and hypotension may occur.<sup>[2-5]</sup> The main toxin responsible for the cardiac effects of mad honey poisoning was GT-I. In addition, the GT-II is capable of spontaneous pulse inhibition on sinoatrial node.<sup>[6]</sup> Grayanotoxin shows the effect of binding to sodium channels in cell membranes, increases the permeability of sodium channels in the cell membranes, as a result depolarization time will get longer.<sup>[7]</sup> Continuous action of sodium channels reduce the depolarization, this condition leads to sinus node dysfunction.<sup>[7]</sup>

The most common effects of mad honey are gastrointestinal system symptoms, but bradyarrhythmias and hypotension can also be observed. Except for bradyarrhythmias and hypotension, sweating, dizziness,

altered consciousness, syncope, diplopia, blurred vision, hypersalivation are less common side effects.<sup>[2-5,8]</sup> Atrial fibrillation,<sup>[9,10]</sup> myocardial infarction,<sup>[11]</sup> and complete AV block<sup>[12]</sup> due to the mad honey intoxication have been reported in the literature. Electrocardiographic monitoring, intravenous saline infusion and supportive care consisting of treatment with atropine is sufficient to remedy the symptoms of patients suffering mad honey poisoning.<sup>[2-5]</sup>

In our case, the signs of toxicity was observed approximately one hour after ingestion of honey,. As well as nausea, vomiting and dizziness, myocardial infarction was brought to mind on differential diagnosis because of chest pain. However, the ECG was unremarkable except for the slow ventricular response atrial fibrillation, the enzyme was normal in follow-up, echocardiographic and angiographic examination was normal, therefore, we ruled out probable myocardial infarction. Rapid saline infusion applied to the patient and normal sinus rhythm was restored after 1 mg atropine and during follow-up for 48 hours, no complications were occurred.

## CONCLUSION

Mad honey poisoning may be presented with unexplained bradycardia, hypotension, and non specific electrocardiographic changes including rhythm disorders can be observed during the poisoning. In the differential diagnosis, mad honey poisoning should be kept in mind. Bradycardia and very rarely slow ventricular response atrial fibrillation can be observed due to the ingestion of mad honey as in our case.

## REFERENCES

- Gunduz A, Bostan H, Turedi S, Nuhoglu I, Patan T. Wild flowers and mad honey. *Wilderness Environ Med* 2007;18:69-71.
- Gündüz A, Turedi S, Uzun H, Topbas M. Mad honey poisoning. *Am J Emerg Med* 2006;24:595-8.
- Koca I, Koca AF. Poisoning by mad honey: A brief review. *Food Chem Toxicol* 2007;45:1315-4.
- Volkan H, Serhat B, Nihat K, Sami A, Serhan Y, Işıl ÖT. Mad Honey Poisoning in Zonguldak Province: Analysis of 72 cases. *J Turk Anaesth Int Care* 2010;38:278-84.
- Özhan H, Akdemir R, Yazici M, Gündüz H, Duran S, Uyan C. Cardiac emergencies caused by honey ingestion: A single centre experience. *Emerg Med J* 2004;21:742-4.
- Onat FY, Yegen BC, Lawrence R, Oktay A, Oktay S. Site of action of grayanotoxin in mad honey in rats. *J Appl Toxicol* 1991;11:199-201.
- Maejima H, Kinoshita E, Seyama I, Yamaoka K. Distinct sites regulating grayanotoxin binding and unbinding to D4S6 of Na(v)1.4 sodium channel as revealed by improved estimation of toxin sensitivity. *J Biol Chem* 2003;278:9464-71.
- Yilmaz O, Eser M, Sahiner A, Altintop L, Yesildag O. Hypotension, bradycardia and syncope caused by honey poisoning. *Resuscitation*

- 2006;68:405-8.
9. Bayram NA, Keles T, Durmaz T, Dogan S, Bozkurt E. A Rare Cause of Atrial Fibrillation: Mad Honey Intoxication. J Emerg Med 2011 Nov 4. [Epub ahead of print]
  10. Cakar MA, Can Y, Vatan MB, Demirtas S, Gunduz H, Akdemir R. Atrial fibrillation induced by mad honey intoxication in a patient with Wolf-Parkinson-White syndrome. Clin Toxicol (Phila) 2011;49:438-9.
  11. Yildirim N, Aydin M, Cam F, Celik O. Clinical presentation of non-ST-segment elevation myocardial infarction in the course of intoxication with mad honey. Am J Emerg Med 2008;26:108.e1-2.
  12. Dursunoglu D, Gur S, Semiz E. A case with complete atrioventricular block related to mad honey intoxication. Ann Emerg Med 2007;50: 484-5.

**How to cite this article:** Osken A, Yaylaci S, Aydin E, Kocayigit I, Cakar MA, Tamer A, *et al.* Slow ventricular response atrial fibrillation related to mad honey poisoning. J Cardiovasc Dis Res 2012;3:245-7.

**Source of Support:** Nil, **Conflict of Interest:** None declared.